



PATIENT

Loki Fitchburg
Friends of Felines

SPECIES

Feline

BREED

DSH

SEX

Male Intact

AGE

1 year

WEIGHT

10.88lbs

INTERPRETED BY

Maggie Machen
Lamy, DVM
DACVIM (Cardiology)

IMAGING PERFORMED BY

Pamela Harrigan,
RDCS

HOSPITAL NAME

Mass Veterinary Services

REFERRING VET

Dr. Masloski

INVOICE

31454

DATE

6/20/23

PRESENTING CLINICAL SIGNS

History: Loki was noted to have a heart murmur in March when he had an amputation for a severely injured hind leg. He was adopted 2 weeks ago. He is presently doing well with a good appetite and activity level. On exam: NSR, grade IV/VI parasternal murmur, PSS, lung fields clear, compressible thorax, mm pink, moist, CRT<2. Unable to obtain BP. Currently, no medications. *Sedated with propofol for study.

ECHOCARDIOGRAM FINDINGS

2D, m-mode, color flow and Doppler imaging is available.

Left ventricle: The LV chamber is normal with adequate myocardial function. The LV wall thicknesses are mildly increased. There is a diffusely hyperechoic endocardium consistent with fibrosis. The papillary muscles are moderately hypertrophied and hyperechoic. The endocardium appears mildly remodeled.

Left atrium: The left atrium is normal.

Mitral valve: The anterior leaflet of the mitral valve appears mildly thickened. Systolic anterior motion is seen on 2D imaging. Mild to moderate eccentric MR.

Aortic valve/Aorta: The aortic valve is normal in morphology and mobility. Mildly increased aortic outflow velocity with a dynamic profile. No aortic insufficiency.

Right ventricle: Normal right ventricular diameter and morphology indicating no overt evidence of pulmonary arterial hypertension.

Right atrium: The right atrium is normal in dimension.

Tricuspid valve: The tricuspid valve appears normal with no tricuspid regurgitation.

Pulmonary valve/Pulmonary artery: The pulmonic valve is normal in morphology and mobility. No pulmonic insufficiency. The RVOT velocity is normal.

Pericardium/other: No pericardial or pleural effusion noted. No obvious cardiac masses.

Heart rhythm: ECG reveals a sinus rhythm with an average HR of 115bpm.

2-Dimensional Measurements

Ao diam (cm)	0.9
LA diam (cm)	1.2
LA:Ao (Swe)	1.3
IVS thickness (cm)	0.65
LVID diastole (cm)	1.4
PW thickness (cm)	0.69
LVID systole (cm)	0.5
FS (%)	64

Doppler Measurements

PV Vmax (m/s)	0.9
AoV Vmax (m/s)	3.0
MR Vmax (m/s)	NA
TR Vmax (m/s)	NA
TR PG (mmHg)	NA

INTERPRETATION OF THE FINDINGS

The diagnosis and cause of the murmur is hypertrophic obstructive cardiomyopathy (HOCM). This indicates some degree of LV thickening (mild in this case) with a dynamic LVOT obstruction (SAM). The MV is mildly thickened, which may suggest a valvular component. Regardless, there is no left atrial dilation, indicating the risk for progression to spontaneous CHF and/or a thrombotic event is currently low. No additional issues are identified.

While no medications have been shown to definitively alter long term outcome at this stage of disease, atenolol is often initiated to decrease the outflow obstruction. This is recommended in this case given these findings and a 1-year-old cat. Prognosis is guarded,



PATIENT

Loki Fitchburg
Friends of Felines

although highly variable at this stage of disease. Patient may be risk for progression to CHF, development of blood clots and/or sudden death in the future.

SPECIES

Feline

RECOMMENDATIONS

- If able, administer titrating dose of atenolol: 25mg tablets; Give ¼ tab once daily. Recheck heart rate in 1-2 weeks with target stressed rate of 140-160bpm 12-24 hours post-administration. Increase as needed until target reached.
- Screening BP/T4 if not recently performed.
- Anesthetic risk is considered mildly elevated, with high risk for fluid overload, spontaneous CHF, hypotension, etc. Judicious IV fluid rates are advised to avoid fluid overload. Drugs that stimulate heart rate should be avoided unless clinically necessary (glycopyrrolate, atropine). Avoid ketamine, telazol, acepromazine and Dexdomitor.
- Monitor for any clinical evidence of cardiac compromise, including respiratory changes and/or signs of a blood clot event (paralysis, neurologic changes, etc.).

BREED

DSH

SEX

Male Intact

AGE

1 year

PLAN

- Recommend recheck echocardiogram in 6-12 months to assess rate of progression, sooner if any issues arise in the interim.

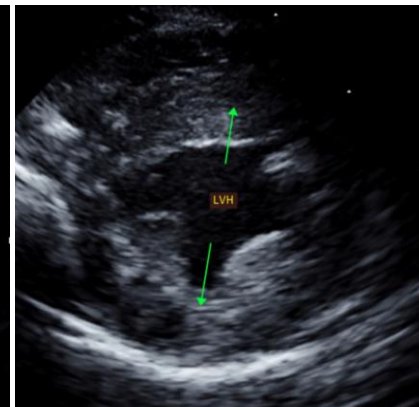
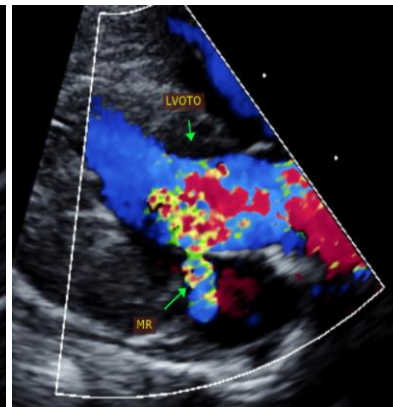
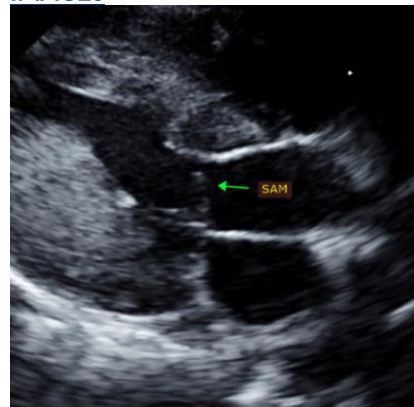
WEIGHT

10.88lbs

IMAGES

INTERPRETED BY

Maggie Machen
Lamy, DVM
DACVIM (Cardiology)



IMAGING PERFORMED BY

Pamela Harrigan,
RDCS

The information and recommendations provided are based on the images presented by the referring veterinarian. No evaluation can be communicated regarding pathology that was not visible in the image/video clips provided.

HOSPITAL NAME

Mass Veterinary
Services

Thank you for this referral. This report was generated using transcription software, and minor dictation errors may be present. If the clinical or image interpretation does not parallel your findings or if I can be of any further assistance, please contact me.

REFERRING VET

Dr. Masloski

Maggie Machen Lamy, DVM
Diplomate of the American College of Veterinary Internal Medicine (Cardiology)
info@sonopath.com

INVOICE

31454

Echocardiogram performed by:

Pamela Harrigan, RDCS
Pet Animal Ultrasound Service (4paus.com)

DATE

6/20/23